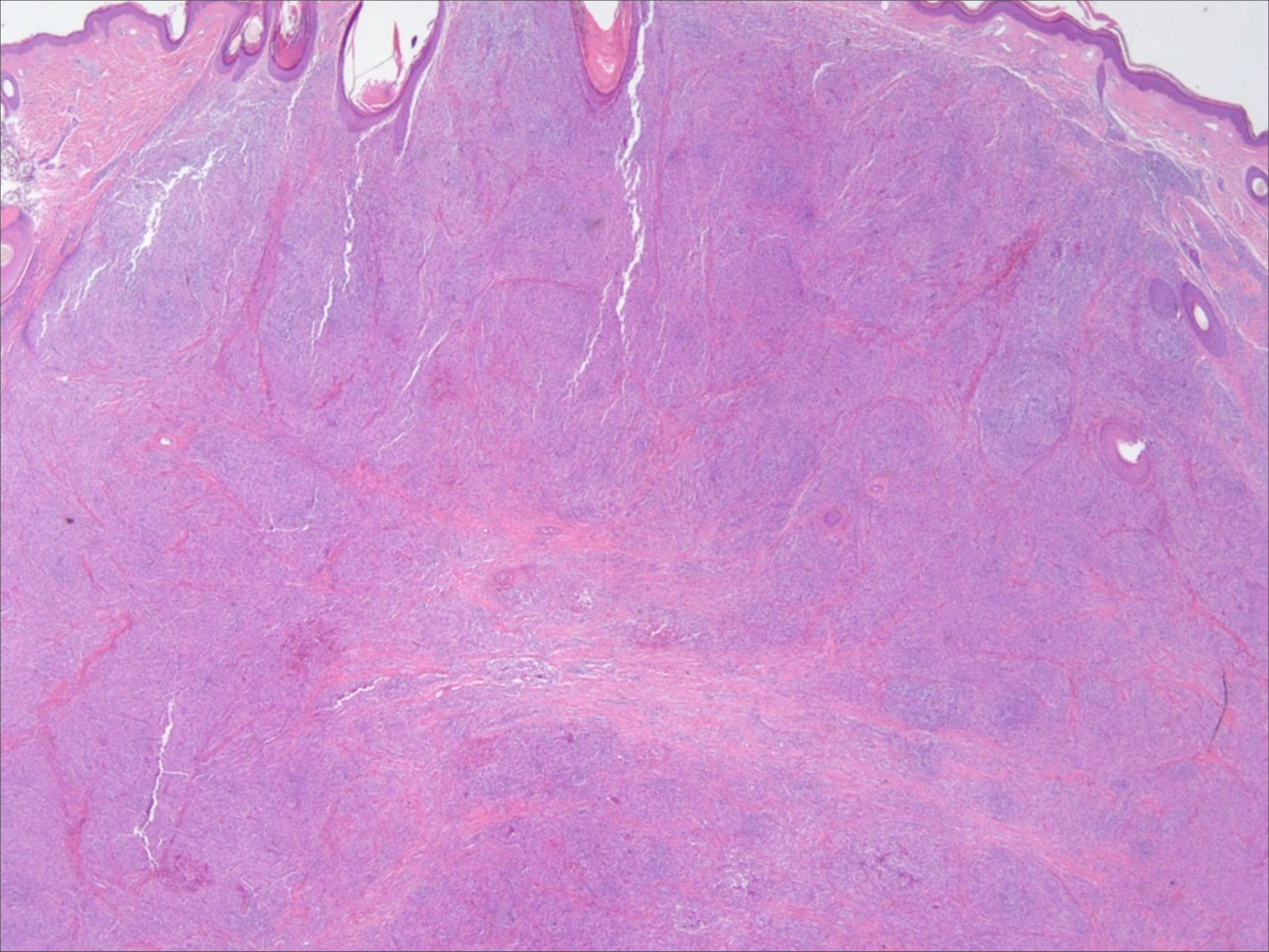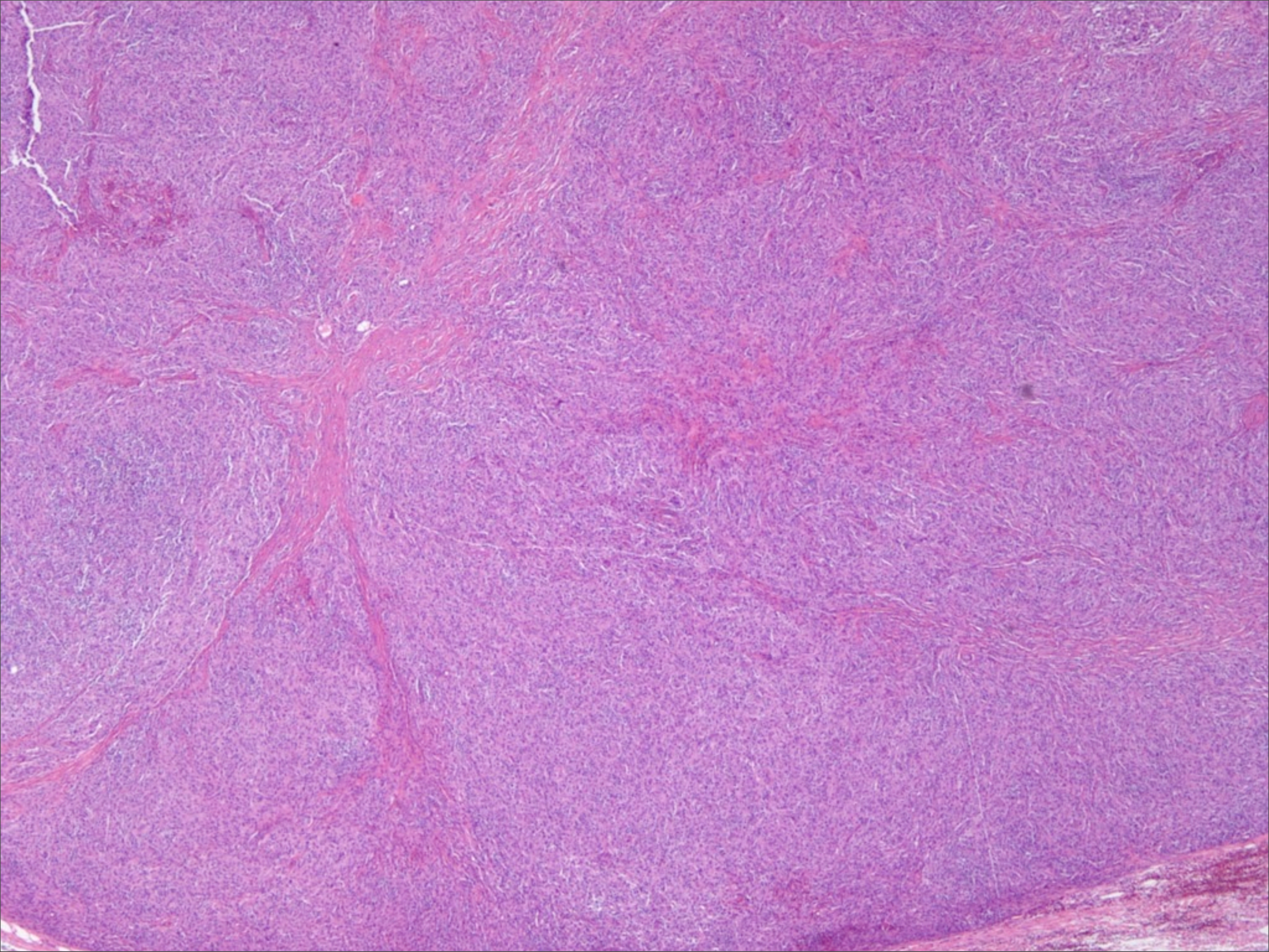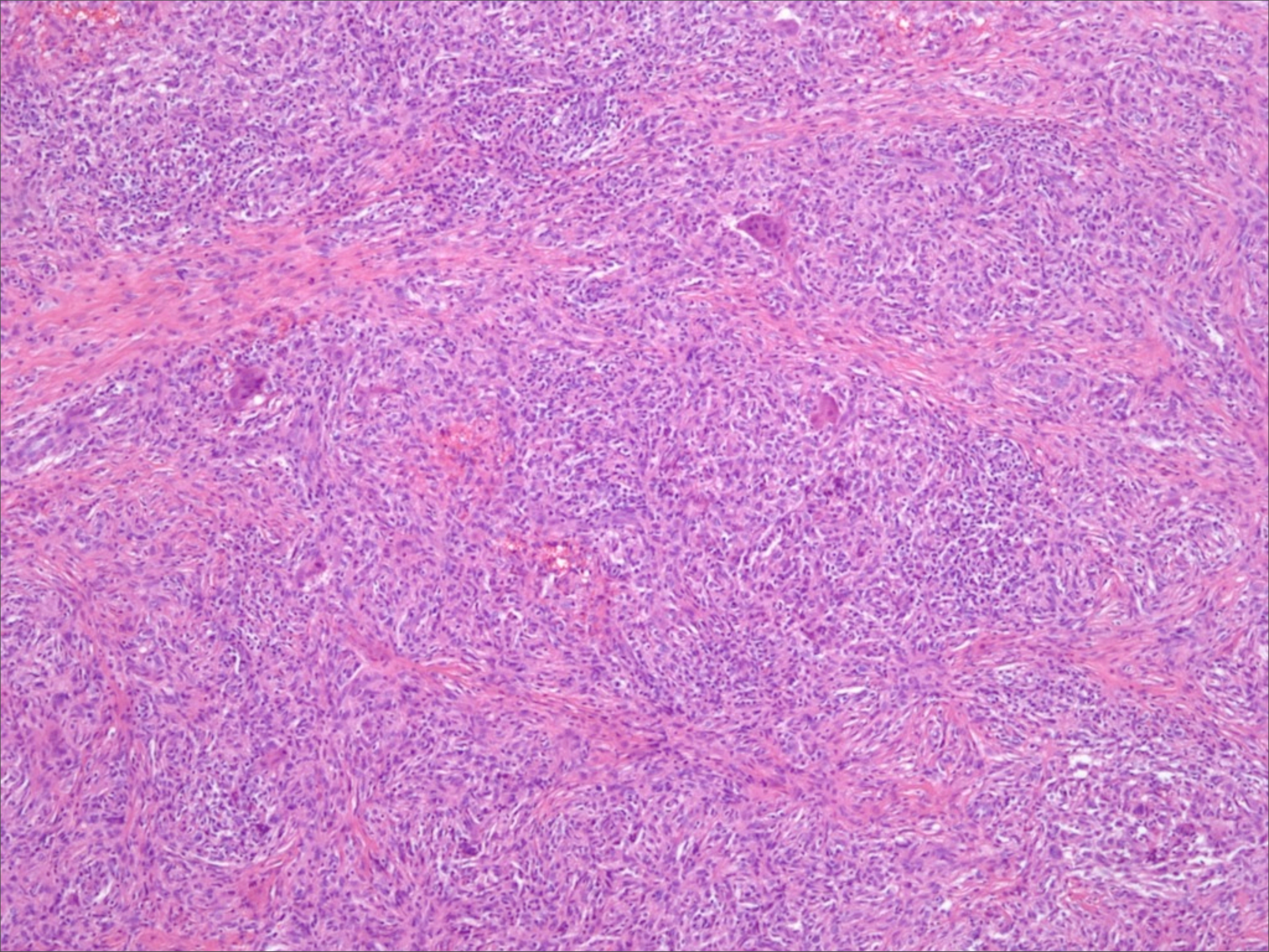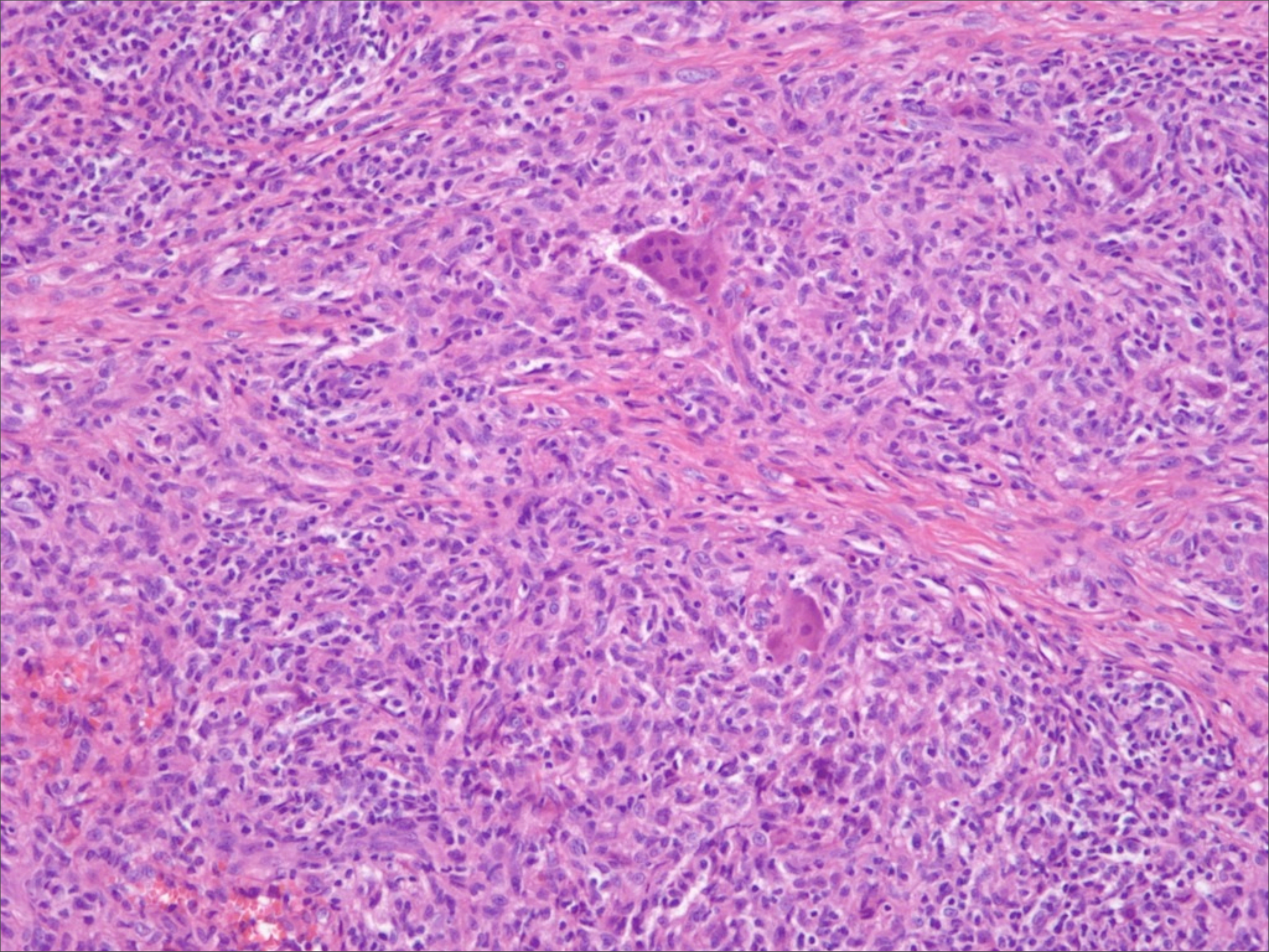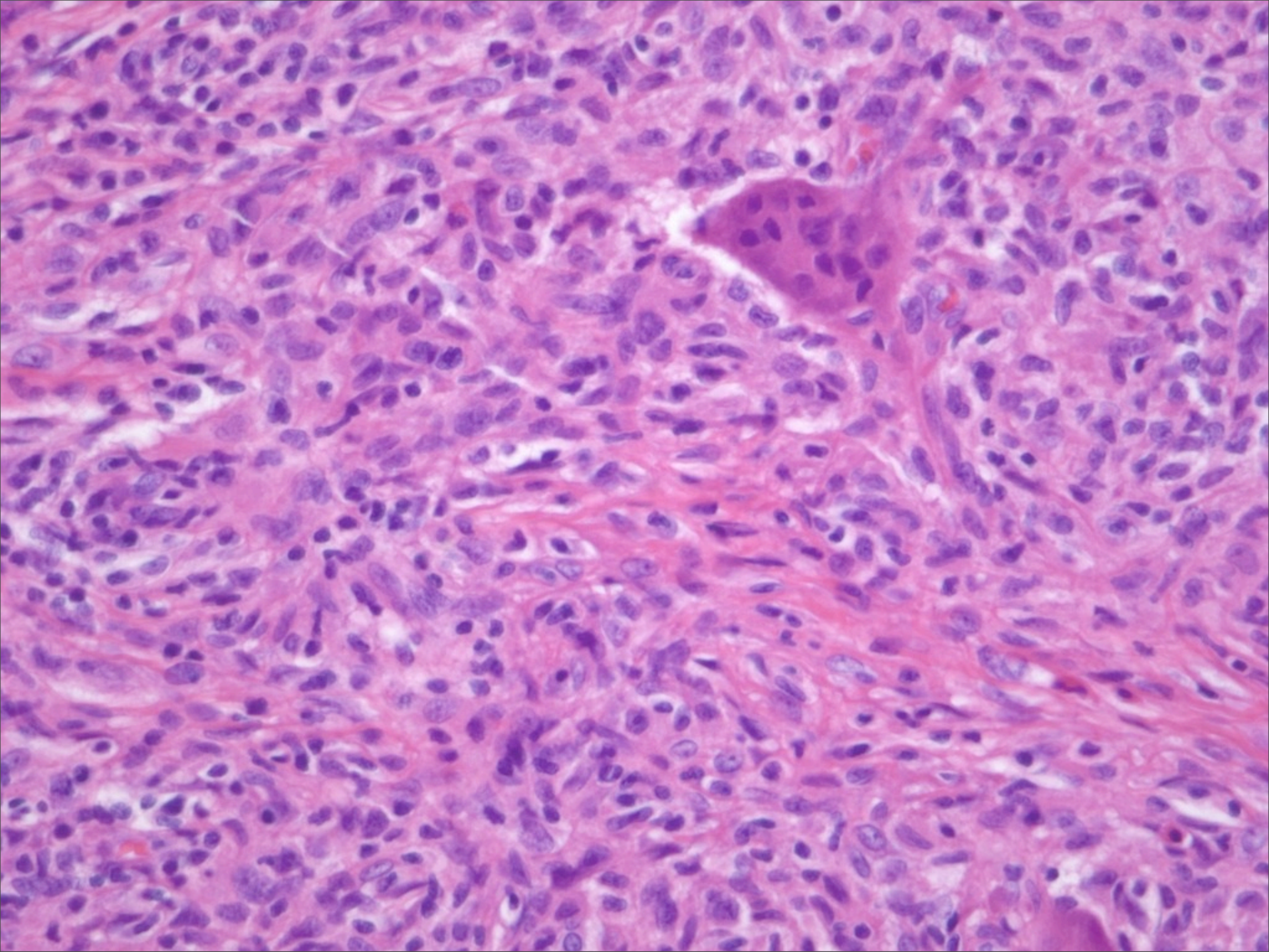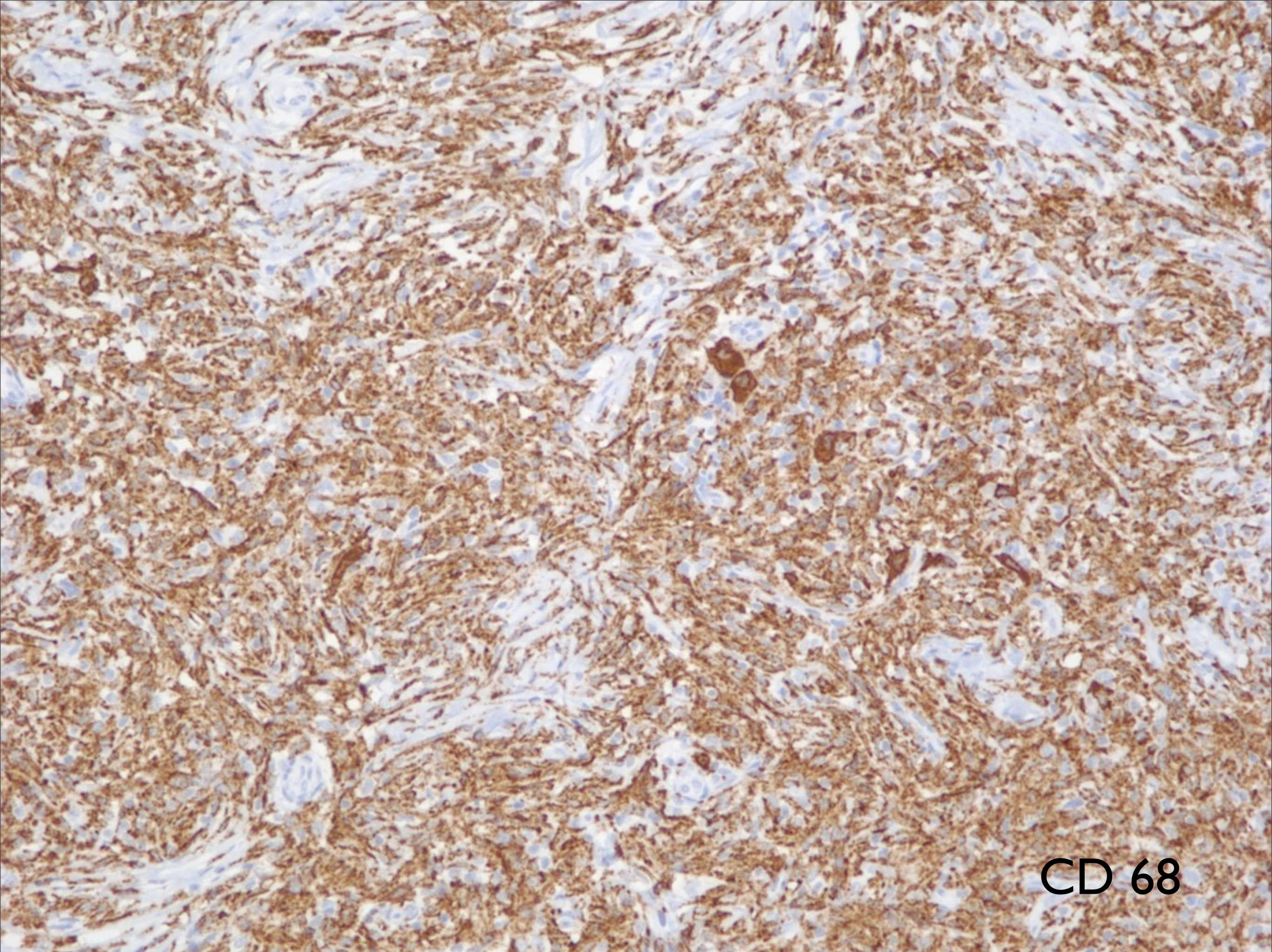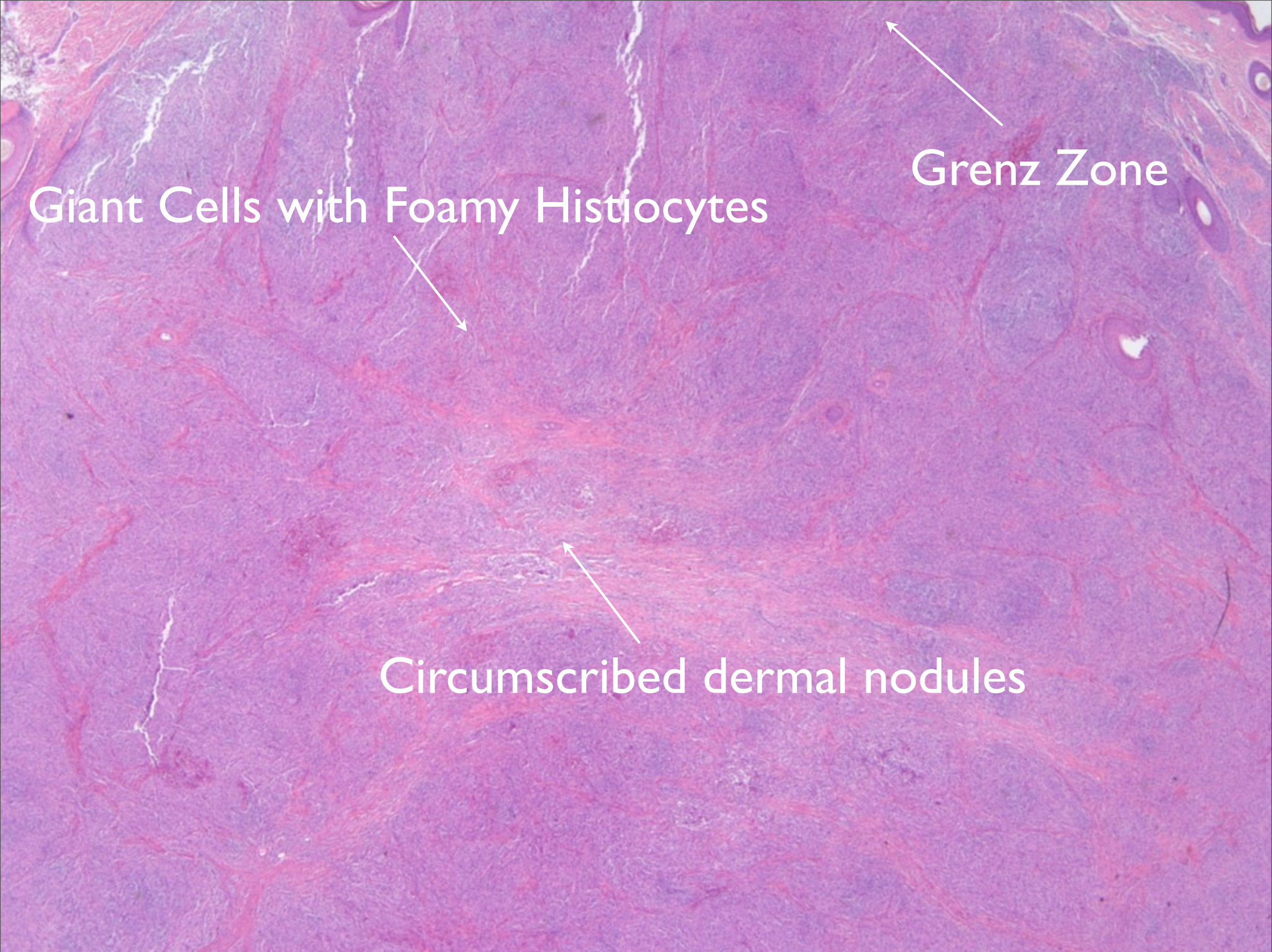


CD 68

Juvenile Xanthogranuloma



Giant Cells with Foamy Histiocytes

Grenz Zone

Circumscribed dermal nodules